

Analyzing Macular Edema In Diabetic Patients

Deepika.K.G¹, Prof.Prabhanjan.S²

¹MTech 4th Sem, SET, JAIN University

² Professor, Dept of ISE, SET, JAIN

ABSTRACT

Diabetic macular edema (DME) is an advanced symptom of diabetic retinopathy and can lead to irreversible vision loss. In this paper, a two-stage methodology for the detection and classification of DME severity from color fundus images is proposed. DME detection is carried out via a supervised learning approach using the normal fundus images. A feature extraction technique is introduced to capture the global characteristics of the fundus images and discriminate the normal from DME images. Disease severity is assessed using the neural networks.

KEYWORDS: Abnormality detection, diabetic macular edema, hard exudates, PCA, Neural network.

I. INTRODUCTION

Image processing is a method to convert an image into digital form and perform some operations on it, in order to get an enhanced image or to extract some useful information from it. It is a type of signal dispensation in which input is image, like video frame or photograph and output may be image or characteristics associated with that image. Usually **Image Processing** system includes treating images as two dimensional signals while applying already set signal processing methods to them. Diabetic macular edema (DME) caused due to diabetes is a high risk complication which can cause irreversible loss of vision [1]–[3]. Early detection of even a minor sign of DME is essential as it may also appear without any external symptoms[4]. Once detected during retinal examination, it demands immediate treatment ranging from glycemic and blood pressure control, to laser surgery. DME is generally detected directly or indirectly. Direct ways are using stereoscopy (for manual examination) or optical computed tomography images [3]. Indirect method is by detecting the presence of hard exudates (HE) in the retina. HE are formed due to secretion of plasma from capillaries resulting from the complications of retinal vasculature and could lead to retinal swelling. In color fundus images they appear as yellow–white deposits (see Fig. 1). Detecting the presence of hard exudates (HE) in different areas of retina is now considered a standard method to assess DME from color fundus images [1], [4], [5].

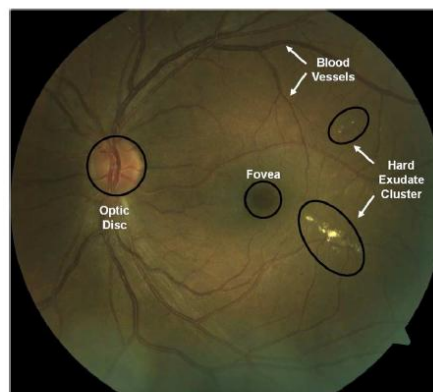


Fig. 1. Color fundus image with anatomical structures and lesions annotated.

The severity of the risk of edema is evaluated based on the proximity of HE to the macula, which is defined to be a circular region centered at fovea and with one optic disc (OD) diameter (see Fig. 1). The risk for DME increases when the HE locations approach the macula, with the risk being the highest when they are within the macula. This is an important factor in DME assessment for further referral of the patients to an expert.

In order to develop a solution for automatic DME assessment, first a decision module is required to validate the presence or absence of HE in a given color fundus image. Once their presence is confirmed, a second module has to assess the macular region for measuring the risk of exhibiting DME. Therefore, in this work, a two-stage methodology for detection and assessment of DME is proposed.

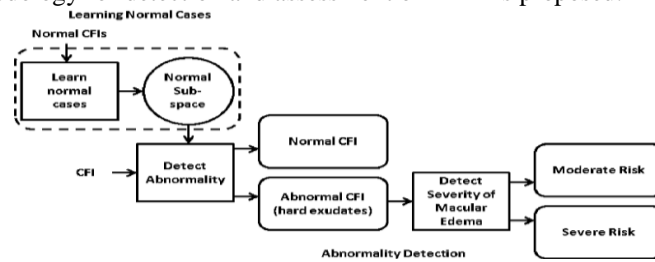


Fig. 2. Processing pipeline for detection and assessment of DME (CFI—color fundus image).

II. PAST WORK

Among recent approaches to direct detection of edema from color fundus images, multiple uncalibrated fundus images have been used to estimate a height map of macula in [2]. The estimated height map is generally noisy. A difference in the mean height is demonstrated between the height maps of normal and edema cases on synthetic images and only four sets of color fundus images. This difference is used to determine normal and abnormal cases. While the proposed method is encouraging, it requires more rigorous validation. Our strategy for detecting macular edema and evaluating its severity is as follows: the image under evaluation is first ascertained to be normal (abnormality detection) (see Fig. 2) by learning the characteristics of normal retinal images. Any deviation from normal characteristics is taken to be indicative of abnormality. For every abnormal image the severity of DME is assessed by determining the location of HE relative to the macula. In the next section, a detail of the proposed method is presented. HE appear as clusters of bright, high contrast lesions and are usually well localized. This observation is used to derive relevant features to describe the normal and abnormal cases. Given a color fundus image, a circular region of interest (ROI) is first extracted and an intermediate representation also known as the motion pattern of the ROI is created. Relevant features are then derived for to classify the given image as normal or abnormal (containing HE).

The significant contributions of this work are: 1) a hierarchical approach to the problem, 2) a novel representation for the first level, to classify an image as normal/abnormal (containing HE), and 3) a rotational asymmetry measure for the second level, to assess the severity of risk of DME. The novel representation captures the global image characteristics. Such global features have not been used successfully earlier for HE detection. In the first level, a supervised technique based on learning the image characteristics of only normal patients is used for detecting the abnormal cases pertaining to HE. This approach has the inherent advantage of reducing the effort of building a CAD system by removing the need for annotated (at the lesion level) abnormal images. Such annotations are required for both supervised and unsupervised classification schemes in order to find suitable system parameters for detection. The approach facilitates separating the normal patients from those showing disease symptoms, as practiced in DR screening [9]. There is no preprocessing the original images or postprocessing the results is done to handle the false alarms due to variability observed across color fundus images. This is due to the proposed global features.

III. PROPOSED WORK

HE appears as clusters of bright, high contrast lesions and are usually well localized. The macula is a dark structure roughly at the center of the retina. In the absence of any HE, there is a rough rotational symmetry about the macula in the circular region of roughly twice the diameter of the optic disc. This observation is used to derive relevant features to describe the normal and abnormal case: 1) Region of Interest Extractions, 2) Preprocessing, 3) Feature Extraction, 4) Determining the Severity of Macular Edema.

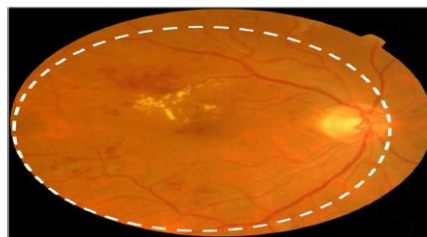


Fig. 3. Sample fundus image and the circular region of interest centered on macula.

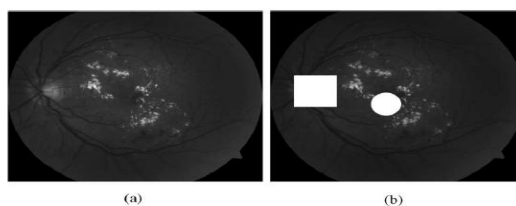


Fig. 4. Sample images (green channel) and result of macula and optic disk detection. OD is indicated by a bright rectangular mask and the macula location by a circular mask. (a) Sample image A (b) Detected macula and OD for sample image A.

[1] Region of Interest Extractions:

Since the severity of DME is determined based on the location of HE clusters relative to the macula, the images acquired for DME detection usually focus around the macular region. We consider the best fit circle within the fundus image with macula at the center, for a given image. The region within this circle is the desired ROI denoted as (see Fig. 3 for an example). The green channel of forms the input for all subsequent processing. The acquired images for DME detection are macula centric. The OD shares a brightness characteristic similar to HE, The macula is shown as a circular patch and the OD is shown as a rectangular patch.

[2]Preprocessing

Applying a green component to the histogram equalization and a grayscale closing operator ($\ominus p$) on the histogram image 1 will help eliminate the vessels which may remain in the optic disc region.

$$I_2 = \ominus p (B \ominus 1) (1) (6)$$

Where B1 is the morphological structuring element. The resulting image I_2 is binarized by thresholding (a_1). After, we remove from the binary image all connected components that have fewer than P pixels, producing another binary image; P is chosen such that it is smaller than the maximum size of the optic disc centre in the fundus image. The resulting image optic disc and border removal is obtained which is AND operated with the dark features for obtaining the exudates.

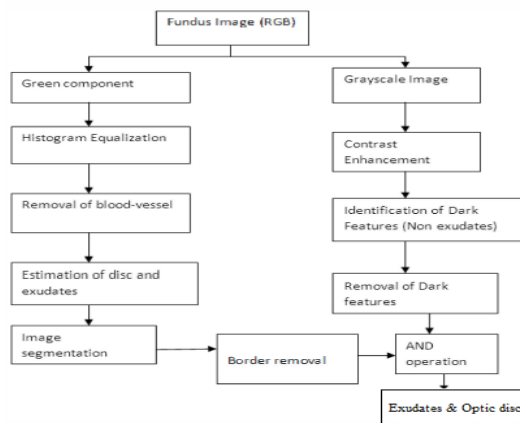
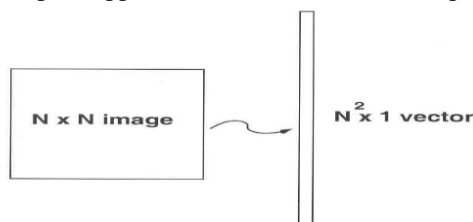


Fig 5: Block diagram for preprocessing

[3] Feature Extraction

PCA is used for feature extraction. It is based on the assumption that high information corresponds to high variance. After the extraction of PCA features, original data is projected to a new coordinate space, and each coordinate axis in the new coordinate space represents a principal component vector. Principal component analysis (PCA) was performed for reducing dimensions in feature data processing. PCA is to convert a set of observations of possibly correlated variables into a set of values of linearly uncorrelated variables using an orthogonal transformation. The simplest approach is to think of it as a template matching problem:



Problems arise when performing recognition in a high-dimensional space. - Significant improvements can be achieved by first mapping the data into a *lower dimensionality* space.

Computation of the eigenvalues:

Step 1: obtain fundus images of eyes (training data).

(**Very important:** the fundus images must be of the same *size*)

Step 2: represent every image as a vector A.

Step 3: compute the average vector:

```
avg = ((sum (A))/counter);
```

Step 4: subtract the mean value:

```
B=double (A);
for i=1:counter
    B (i,:) = B(i,:) - avg;
end
```

Step 5: compute the covariance matrix C:

```
C=B*B';
cmax=max(max(C));
C=C/cmax;
```

Step 6: compute the eigenvectors

```
[E,D] = eig(C);
clear D;
E=fliplr(E);
egneye=E*B;
```

Step 7: Weight vector calculation: calculates weight factors of a eye image based on eigen eyes.

```
function [wv]=itw(I1,egneye,cnt,avg)
    Iv=double(reshape(I1,1,size(I1,1)*size(I1,2)));
    Iv=Iv-avg;
    for k=1:cnt
        wv(k)=dot(egneye(k,:),Iv);
    end
```

[4] Determining the Severity of Macular Edema.

Neural network models attempt to simulate the information processing that occurs in the brain and are widely used in a variety of applications, including automated pattern recognition. We define a neural network with one input layer, 16(database contains 15 images) hidden layer and one output layer. Neural network is trained using target and pattern obtained from PCA and gives severity as output.

IV DESIGN METHODOLOGY

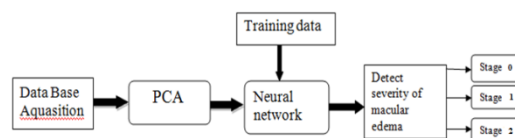


Fig 6: Design model

Data Base Acquisition: This DB contains fundus images that are to be tested for presence of Hard exudates. It is taken as input for the PCA.

PCA (Principal component analysis): PCA is used for feature recognition .The feature vector or eigenvector is the output of PCA.

Training data: In this DB the images of known severity levels are stored. This DB is required for training the neural network.

Neural Network: Neural network is used as classifier. It takes the output vector from PCA and does classification. It gives the severity as output.

V RESULT AND SNAPSHOTS

Database contains 15 images, five from each severity level and there are three severity levels- level 0 (normal), level 1 (moderate) and levels 2 (severe).

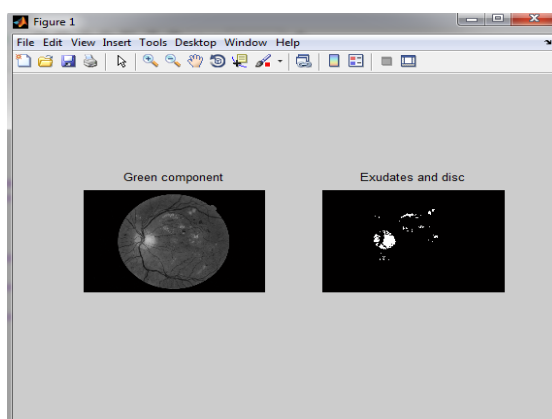


Fig 7: Preprocessed image to obtain exudates and optic disc.

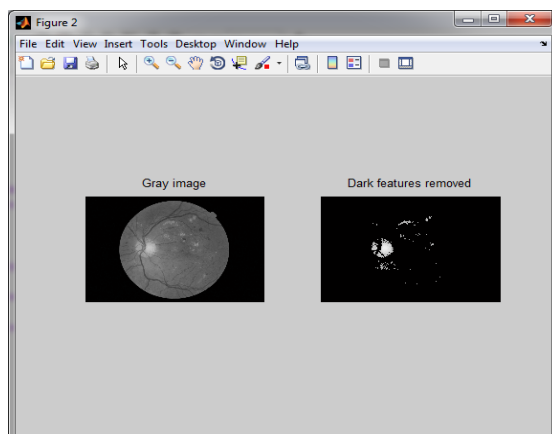


Fig 8: Preprocessed image to remove dark features.

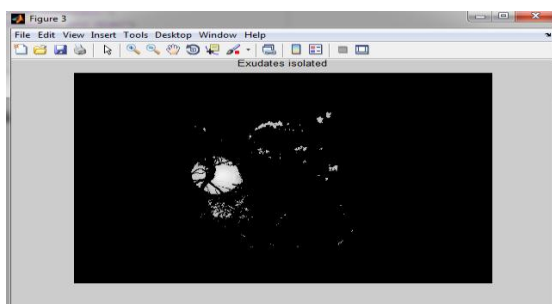


Fig 9: Preprocessed image obtain after performing AND operation for Fig 6 and 7.

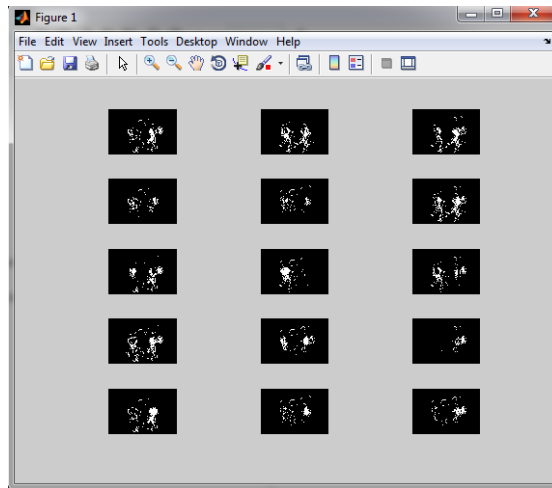


Fig 10: Eigen images obtained after applying PCA to database.

0.2643	-0.1101	-0.0239	-0.0448	-0.0614	-0.0394	0.1407	-0.3913
-0.2983	0.0106	0.2342	0.0860	0.0281	0.2820	-0.0704	0.6492
-0.1515	0.0232	-0.0040	-0.0320	-0.1732	-0.1771	-0.0277	0.3658
0.1295	0.0552	0.0730	0.0022	-0.0867	0.0926	-0.0600	-0.1552
-0.1130	0.0570	-0.0477	0.0429	-0.2042	0.1010	-0.0670	0.2363
0.1742	0.3654	-0.0118	0.0387	-0.0751	-0.0990	-0.0775	-0.1883
0.2650	-0.1638	0.0027	-0.0500	-0.0634	-0.0551	0.2078	-0.4332
0.1429	-0.0452	0.0294	-0.0617	-0.0583	-0.0895	0.3243	-0.6508
0.2337	0.1122	0.0042	-0.1093	0.0108	-0.0062	0.1984	-0.5576
1.0073	-0.0464	-0.5662	0.2232	0.6416	-0.2244	-0.3537	-0.5557
-1.3923	-0.1717	-0.1161	0.2456	0.4175	-0.0394	-0.0615	1.0569
-0.2675	0.1190	0.2784	0.0592	-0.0373	0.1874	-0.0636	1.0922
-0.0332	-0.0360	0.1310	-0.2469	0.0535	0.2307	-0.0498	0.1104
-0.0517	0.0182	0.1074	0.0273	-0.2626	0.0962	-0.0674	0.1751
0.0906	-0.1876	-0.0905	-0.1654	-0.1292	-0.2659	0.0273	-0.7838

Columns 9 through 15

0.1433	0.2936	-0.2966	-0.1662	-0.2604	-0.2128	-0.0603
-0.1064	-0.5962	-0.0380	0.2556	0.3704	0.1648	0.2527
0.1565	-0.1669	0.4496	0.1294	0.1751	-0.0532	0.3753
0.0787	0.0978	0.1822	-0.3265	0.2391	-0.0319	-0.0625
0.0457	-0.0828	0.2454	0.1319	0.2255	-0.0202	0.2074
0.1247	0.1185	0.1230	-0.5576	0.5490	0.0228	-0.2092
0.2264	0.1831	-0.1456	0.0057	-0.2299	-0.2659	-0.4052
-0.0510	0.2238	-0.2342	-0.0941	-0.3095	-0.2685	-0.1278
0.1209	0.2504	-0.2371	-0.1035	-0.5500	-0.1918	-0.2003
-0.3039	0.2921	-0.0947	0.0582	-0.8673	0.5681	-0.0749
0.1044	-0.2984	0.2093	0.4707	0.3543	0.5096	0.3637
-0.5219	-0.2730	0.0793	0.3141	0.2755	-0.0269	0.0863
0.0199	-0.0810	0.0228	0.0140	0.3026	0.1108	0.0635
0.0407	-0.1086	0.1522	0.0871	0.2128	0.1341	0.1520
-0.0780	0.1476	-0.4174	-0.2159	-0.4870	-0.4394	-0.3605

Fig 11: weight matrix (15X15) required to train neural network.

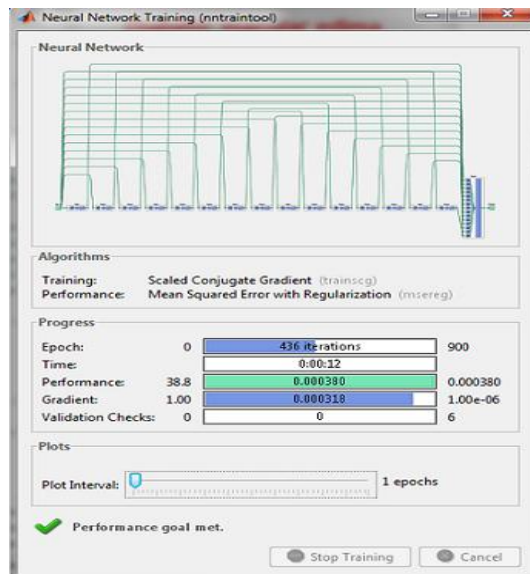


Fig 12: Training of Neural Network with one input layer, 16 output layer and one output Layer.

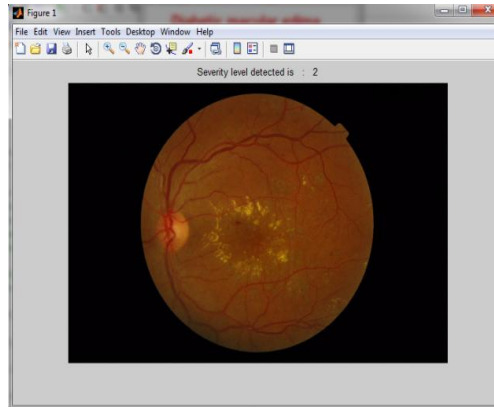


Fig 13: outcome of this project-After training neural network we can select the test image and this image shows the severity level as 2(severe).

VI CONCLUSION

This project has proposed and evaluated a method for DME detection and assessment. The significant contributions of this work are: 1) a hierarchical approach to the problem, 2) In first level PCA is applied for feature extraction.3) Neural network for the second level, to assess the severity of risk of DME. The approach facilitates separating the normal patients from those showing disease symptoms. The proposed method is shown to be effective in detecting DME for challenging cases.

In the second level, the severity of the is assessed analyzing the output of neural network. This level facilitates the decision to recommend a patient to a medical expert, based on the proximity of HE to the center of macula. The proposed methodology enhances the existing DR screening infrastructure by helping automate the detection and assessment of DME.

REFERENCES

- [1] L. Giancardo, F. Meriaudeau, T. P. Karnowski, Y. Li, K. W. Tobin, Jr., and E. Chaum, "Automatic retina exudates segmentation without a manually labelled training set," in Proc. 2011 IEEE Int. Symp. Biomed. Imag: From Nano to Macro, Mar. 2011, pp. 1396–1400.
- [2] L. Giancardo, F. Meriaudeau, T. Karnowski, K. Tobin, E. Grisan, P. Favaro, A. Ruggeri, and E. Chaum, "Textureless macula swelling detection with multiple retinal fundus images," IEEE Trans. Biomed. Eng., vol. 58, no. 3, pp. 795–799, Mar. 2011.
- [3] M. R. Hee, C. A. Puliafito, C. Wong, J. S. Duker, E. Reichel, B. Rutledge, J. S. Schuman, E. A. Swanson, and J. G. Fujimoto, "Quantitative assessment of macular edema with optical coherence tomography," Arch. Ophthalmol., vol. 113, no. 8, pp. 1019–1029, Aug. 1995.
- [4] J. Davidson, T. Ciulla, J. McGill, K. Kles, and P. Anderson, "How the diabetic eye loses vision," Endocrine, vol. 32, pp. 107–116, Nov. 2007.
- [5] C. P. Wilkinson, F. L. Ferris, R. E. Klein, P. P. Lee, C. D. Agardh, M. Davis, D. Dills, A. Kampik, R. Pararajasegaram, and J. T. Verdager, "Proposed international clinical diabetic retinopathy and diabetic macular edema disease severity scales," Am. Acad. Ophthalmol., vol. 110, no. 9, pp. 1677–1682, Sep. 2003.
- [6] R. F. N. Silberman, K. Ahlrich, and L. Subramanian, "Case for automated detection of diabetic retinopathy," Proc. AAAI Artif. Intell. Development (AI-D'10), pp. 85–90, Mar. 2010.
- [7] M. Verma, R. Raman, and R. E. Mohan, "Application of tele ophthalmology in remote diagnosis and management of adnexal and orbital diseases," Indian J. Ophthalmol., vol. 57, no. 5, pp. 381–384, Jul. 2009.
- [8] M. D. Abramoff, M. Niemeijer, M. S. Suttorp-Schulten, M. A. Viergever, S. R. Russell, and B. van Ginneken, "Evaluation of a system for automatic detection of diabetic retinopathy from color fundus photographs in a large population of patients with diabetes," J. Diabetes Care, vol. 31, no. 2, pp. 193–198, Nov. 2007.
- [9] S. Philip, A. Fleming, K. Goatman, S. Fonseca, P. McNamee, G. Scotland, G. Prescott, P. F. Sharp, and J. Olson, "The efficacy of automated disease/no disease grading for diabetic retinopathy in a systematic screening programme," Br. J. Ophthalmol., vol. 91, no. 11, pp. 1512–7, Nov. 2007.